

## ■ Use of 4-Dimensional Sonography in the Measurement of Fetal Great Vessels in Mediastinum to Distinguish True- From False-Positive Coarctation of the Aorta

**To the Editor:** We read with great interest the study “Measurement of the Great Vessels in the Mediastinum Could Help Distinguish True-From False-Positive Coarctation of the Aorta in the Third Trimester,”<sup>1</sup> published in the October 2009 issue. In this article, the authors described a technique allowing the identification of coarctation of the aorta (CoA) by measuring the ratio between the pulmonary artery (PA) and ascending aorta (AO) at the level of the fetal mediastinum. Prenatal diagnosis of CoA is one of the most challenging topics in obstetric ultrasound, and this condition is either frequently missed or associated with false-positive diagnosis.<sup>2</sup> This is mainly due to the difficulties of the operator to properly visualize the great arteries in the presence of a disproportion between ventricular size. Because prenatal identification of CoA is of paramount importance for early neonatal treatment to substantially reduce neonatal mortality,<sup>3</sup> methods simplifying its diagnosis would be extremely beneficial.

Four-dimensional (4D) sonography with spatiotemporal image correlation (STIC), by allowing acquisition of the fetal cardiac volume and reconstruction of a cine loop cardiac cycle from which different cardiac planes can be identified and analyzed,<sup>4</sup> reduces operator dependency. There is evidence that this approach may help in the identification of CoA.<sup>5</sup>

We tested this new technique on 18 fetuses with ventricular disproportion selected from our 4D cardiac volume database. None of the fetuses showed associated congenital heart anomalies. The mean gestational age at 4D acquisition was 30 weeks (range, 26–34 weeks). Diagnosis of CoA was confirmed postnatally in 8 cases, while in the remaining 10 fetuses, a normal heart was shown.

Four-dimensional volumes of the fetal heart were acquired by the STIC technique with a Voluson E8 ultrasound machine (GE Healthcare, Kretztechnik, Zipf, Austria) equipped with a 4- to 8-MHz transducer, according to a previously reported technique,<sup>6</sup> starting with a reference plane from the 4-chamber view. Volumes were analyzed offline with the use of 4D View version 9.0 software (GE Healthcare, Kretztechnik). From the 4-chamber view in plane A, scrolling was performed through the volume data set along the plane of acquisition toward the fetal neck, as indicated by Espinoza et al<sup>7</sup> (Videos 1 and 2). When the 3-vessel view section was identified in plane A, the sizes of both the PA before its bifurcation and the AO were obtained (Figure 1). The PA/AO ratio was significantly lower in fetuses with CoA compared to those with a normal heart (mean  $\pm$  SD,  $2.12 \pm 0.36$  versus  $1.31 \pm 0.28$ ;  $t = 5.37$ ;  $P < .0001$ ).

Our findings confirm the data of Slodki et al<sup>1</sup> and support the value of 4D echocardiography in identifying true CoA among fetuses with ventricular disproportion.

**Giuseppe Rizzo, MD**

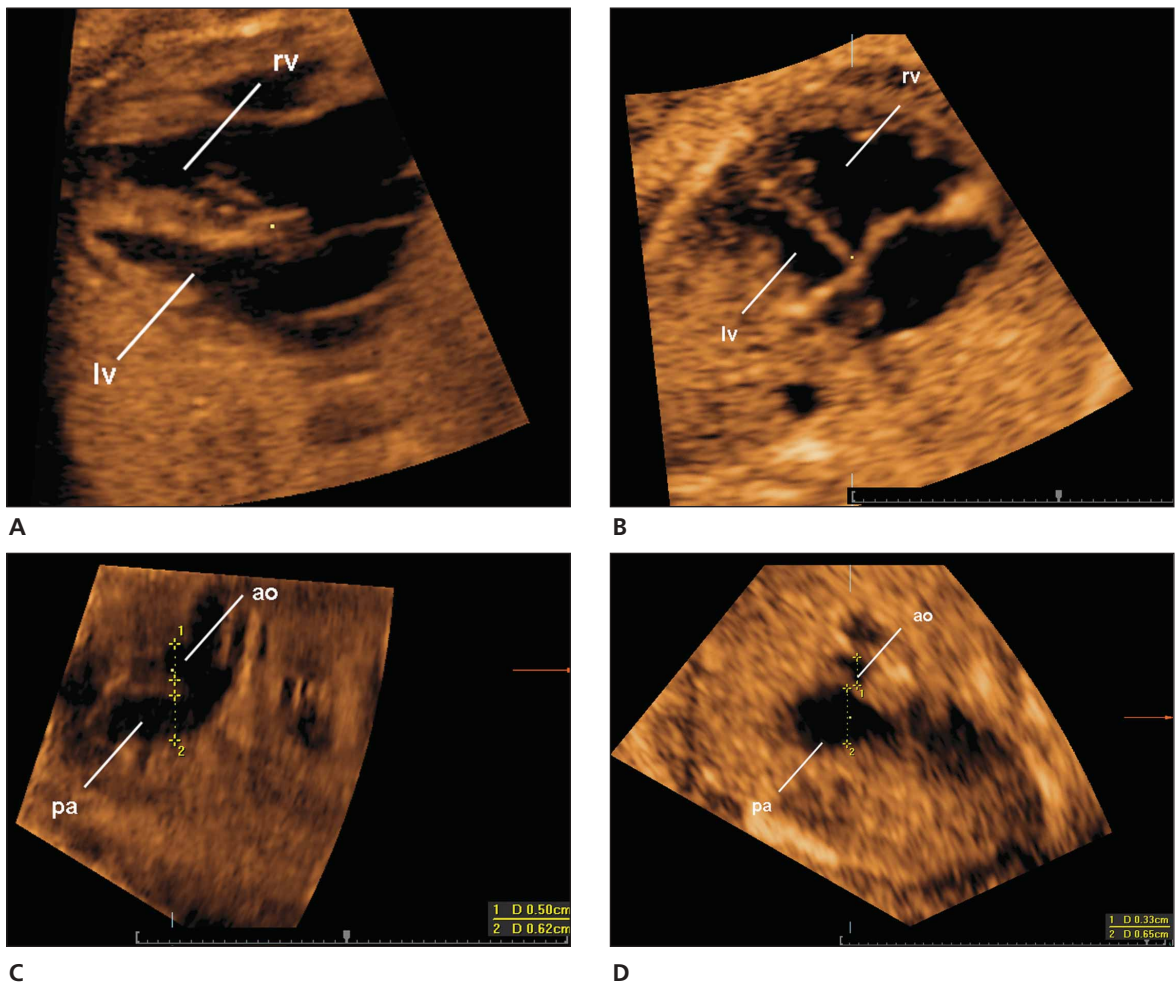
**Domenico Arduini, MD**

Department of Obstetrics and Gynecology  
University of Rome Tor Vergata  
Rome, Italy

E-mail: giuseppe.rizzo@uniroma2.it

**Alessandra Capponi, MD**

Department of Obstetrics and Gynecology  
G. B. Grassi Hospital  
Rome, Italy



**Figure 1.** Multiplanar displays of the 4-chamber view of 2 fetuses with evident ventricular disproportion; ao indicates ascending aorta; lv, left ventricle; pa, pulmonary artery; and rv, right ventricle. **A**, Fetus with a postnatal diagnosis of a normal heart. **B**, Fetus with CoA. **C** and **D**, Multiplanar displays of the 3-vessel views of, respectively, the fetus in **A** (normal heart) with a PA/AO ratio of 1.07 and the fetus in **B** (CoA) with a PA/AO ratio of 1.97.

**References**

1. Slodki M, Rychik J, Moszura T, Janiak K, Respondek-Liberska M. Measurement of the great vessels in the mediastinum could help distinguish true- from false-positive coarctation of the aorta in the third trimester. *J Ultrasound Med* 2009; 28:1313–1317.
2. Allan LD. Left heart malformations. In: Yagel S, Silverman NH, Gembruch U (eds). *Fetal Cardiology*. 2nd ed. New York, NY: Informa Healthcare; 2009:291–303.
3. Franklin O, Burch M, Manning N, Sleeman K, Gould S, Archer N. Prenatal diagnosis of coarctation of the aorta improves survival and reduces morbidity. *Heart* 2002; 87:67–69.
4. Rizzo G, Arduini D. *4D Fetal Echocardiography*. Oak Park, IL: Bentham Science Publishers Ltd. In press. <http://www.bentham.org/ebooks>.
5. Espinoza J, Romero R, Kusanovic JC, et al. Prenatal diagnosis of coarctation of the aorta with the multiplanar display and B-flow imaging using 4-dimensional sonography. *J Ultrasound Med* 2009; 28:1375–1378.
6. Rizzo G, Capponi A, Muscatello A, Cavicchioni O, Vendola M, Arduini D. Examination of the fetal heart by four-dimensional ultrasound with spatiotemporal image correlation during routine second-trimester examination: the “three-steps technique.” *Fetal Diagn Ther* 2008; 24:126–131.
7. Espinoza J, Hassan SS, Gotsch F, et al. A systematic approach to the use of the multiplanar display in evaluation of abnormal vascular connections to the fetal heart using 4-dimensional ultrasonography *J Ultrasound Med* 2007; 26:1461–1467.